

# An Unusual Finding of Proliferative Periostitis in a Child: a Case Report

Saeed Asgary<sup>1,\*</sup>, Mohammad Jafar Eghbal<sup>2</sup>, Sara Ehsani<sup>3</sup>, Behnam Eslami<sup>4</sup>

<sup>1</sup>Iranian Center for Endodontic Research, Dental Research Center, Shahid Beheshti University of Medical Sciences, Tehran, 1983963113, Iran

<sup>2</sup>Dental Research Center, Iranian Center for Endodontic Research, Shahid Beheshti University of Medical Sciences, Tehran, 1983963113, Iran

<sup>3</sup>Dental Research Center, Shahid Beheshti University of Medical Sciences, Tehran, 1983963113, Iran

<sup>4</sup>Department of Oral Medicine, Infection, and Immunity, Harvard School of Dental Medicine, Boston, MA, USA

**Abstract** Proliferative periostitis is a pathologic lesion that displays an osteo-productive and proliferative inflammatory response of the periosteum to infection or other irritation. This lesion is a form of chronic osteomyelitis that is often asymptomatic, occurring primarily in children, and found only in the mandible. The lesion can be odontogenic or non-odontogenic in nature. A 12 year-old boy presented with an unusual odontogenic proliferative periostitis that originated from the lower left first molar, however, the radiographic radiolucent area and proliferative response were discovered at the apices of the lower left second molar. The periostitis was treated by single-visit non-surgical endodontic treatment of lower left first molar without antibiotic therapy. The patient has been recalled regularly; the lesion had significantly reduced in size 3-months postoperatively. Extraoral symmetry occurred at approximately one year recall. At the last visit, 2 years after initial treatment, no problems or signs of complications have occurred; the radiographic examination revealed complete resolution of the apical lesion and apical closure of the lower left second molar. Odontogenic proliferative periostitis can be observed at the adjacent normal tooth. Besides, this case demonstrates that non-surgical endodontics is a viable treatment option for management of odontogenic proliferative periostitis.

**Keywords** Endodontics, Proliferative Periostitis, Odontogenic

## 1. Introduction

Proliferative periostitis in long bones was first described by Garré in 1983[1]. The first documented case in dental literature was reported in 1941[2]. The condition is characterized by new bone formation on the periphery of the cortex over an infected area of spongiosa, which is a response of the inner surface of the periosteum to stimulation by a low-grade infection that has spread through the bone and penetrated the cortex. Staphylococci and streptococci are the microorganisms most commonly found in the area. Periapical odontogenic infection is a frequent cause of proliferative periostitis of the jaws, however, the condition is a relatively uncommon dental complication[3].

Wood suggests that for the lesion to develop, the following combination of circumstances must coexist[3]:

- 1- The periosteum must possess a high osteoblastic activity (which is the case in young individuals).
- 2- A chronic infection must exist.

3- A fine balance must be maintained between the resistance of the host body and the virulence of microorganisms so that a mild, chronic infection can continue; invasive enough to stimulate new periosteal bone formation while not severe enough to induce bone resorption.

Eversole noted that the entity occurs exclusively in children (average age of ~11 years)[4]. Proliferative periostitis typically presenting unilaterally in the posterior two thirds of the mandible[5,6]. A male predominance of 1.4 to 1 has been reported. Sporadic cases had been reported in patients in their third decades and in infants[7]. An infected mandibular first permanent molar is the most common etiologic factor[3,8].

There may be a history of pain caused by the odontogenic infection before the swelling develops at the inferior border or other peripheries of the mandible. The swelling typically presents unilaterally in the posterior two thirds of the mandible[5,6] and the most frequent site is the inferior border of the mandible below the first molar. The maxilla is seldom affected. The condition is characteristically solitary, however, a case with simultaneous lesions in all four quadrants has been reported[3].

The swelling usually causes moderate facial asymmetry, and is asymptomatic, with no associated tenderness. With

\* Corresponding author:

saasgary@yahoo.com (Saeed Asgary)

Published online at <http://journal.sapub.org/ijsr>

Copyright © 2012 Scientific & Academic Publishing. All Rights Reserved

the establishment of the chronic infection beneath the periosteum, new bone is laid down and the swelling soon becomes hard. The mass is bony hard in palpation and the appearance of the overlying skin or mucosa is typically normal but it may be moderately inflamed.

Although the length and depth of bone deposits vary, the swelling is characteristically convex. The size may range from about 2 centimetres to involvement of whole length of mandibular body on the affected side. Fever and leukocytosis are occasional features[3].

Unlike other forms of osteomyelitis, usually hyperthermia is absent and the blood sedimentation rate is normal. Also, there is no distinct increase in the white blood cell count or alkaline phosphatase values[9].

On radiographic examination, a smoothly contoured, moderately convex radiopaque lesion can be seen extending from the cortex of the jaw. The space between this new, thin shell of bone and the pre-existing cortex may be quite radiolucent without images of trabeculae. With time, an alternating radiolucent and radiopaque, laminated appearance may be seen, which makes the characteristic radiographic feature of this disease in the occlusal view, known as the "onion skin" appearance[9-11]. The appearance indicates parallel new reactive bone formation which expands the surface of the altered bone. In most reported cases, the adjacent jawbone appears normal on the radiograph, but in some cases, the condition may be accompanied by osteolytic or osteosclerotic osteomyelitis changes and small sequestra may be noticed. Periapical radiographs usually reveal a radiolucent area at the apex of the involved carious tooth[8,12].

Histological examinations show proliferation of new reactive bone on the bone cortex and beneath the periosteum with fibro-osseous pattern and minimal vascular space. One of the characteristics of this new bone is the presence of osteoblastic rimming and osteoid tissue. Also, in the existing fibrous connective tissue the infiltration of chronic inflammatory cells can be seen[13].

This pathologic entity has been described under different clinical terms including chronic diffuse sclerosing osteomyelitis, chronic osteomyelitis with proliferative periostitis, Garré's osteomyelitis, chronic non-suppurative sclerosing osteitis, osteomyelitis sicca, and periostitis ossificans[13]. The term Garré's osteomyelitis has almost completely been rejected by most medical pathologists but still enjoys acceptance in dental field[14].

The general treatment consensus is to extract the offending tooth; however, root canal treatment (RCT) has also been proposed as a viable treatment option for proliferative periostitis[6,9].

In this article, a case of proliferative periostitis is reported radiographically correlated with the lower left second molar. The lesion was completely resolved by one - visit non-surgical endodontic treatment of lower left first molar (which was considered the origin of the lesion). Up to our knowledge, this is a unique case and has not been reported before.

## 2. Case Report

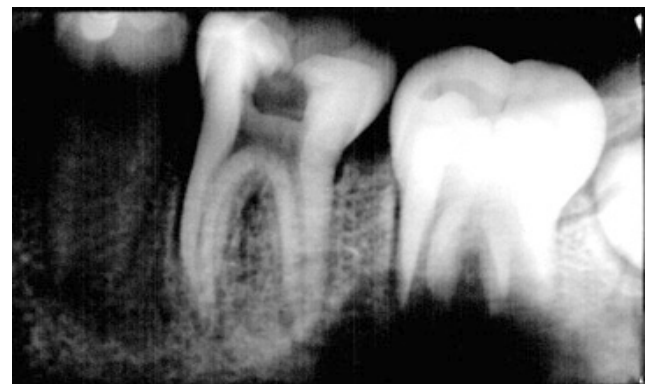A 12-year-old boy was referred for evaluation of a swelling on the left posterior mandibular region, which had come to notice a few months ago. His medical history revealed no present or past record of disease or problems. The patient and his parents reported no history of intraoral or extraoral trauma. He had had no previous experience of dental treatment.

In clinical observation, the patient had an apparently normal general and local growth and development. Extraoral palpation of the lesion revealed a hard, non-fluctuant, smooth swelling, with no associated tenderness. The size of the palpable swelling was approximately 3×4 centimetres. The appearance and colour of the facial skin was normal and lymphatic nodes showed no signs of swelling on visual and tactile examination.

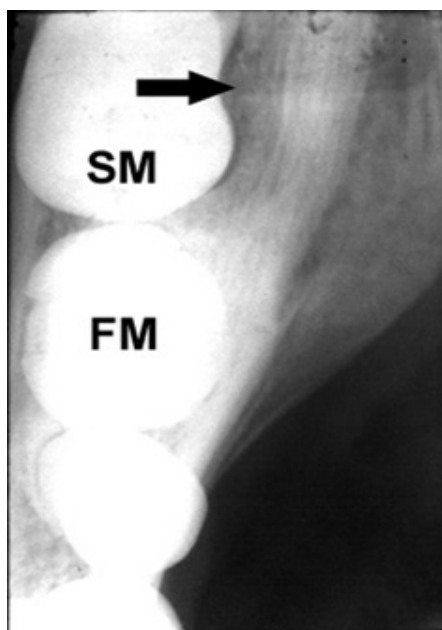
Intraoral examination revealed a large mass on the mucobuccal area of left mandibular molars region; the overlying mucosa had normal colour and appearance. The lower left second molar was sound; however, the lower left first molar had a deep and extensive class I carious cavity. None of the teeth in the region displayed mobility.

The periapical radiographic examination demonstrated a large poorly defined radiolucent lesion around the apices of the lower left second molar (Figure 1); the apices were both immature. Surprisingly, the mandibular first molar showed only mild PDL widening around the tooth and the lamina dura at the apical part of the distal root was blended into the radiolucent lesion. Occlusal radiographic view illustrated a series of radiopaque lines, resulted by formation of periosteal new bone and the characteristic "onion skin" appearance in the second molar region (Figure 2).

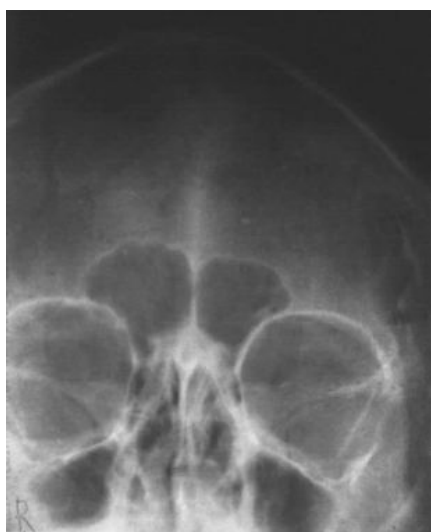The patient reported no fever and all blood tests including complete blood count (CBC), Wright, Vidal, and Tuberculin tests were within normal range. Panoramic, skull and chest X-rays were ordered to rule out other possible diseases (Figures 3-4). The diagnosis was set as proliferative periostitis due to pulp/periapical infection. Despite the fact that in all radiographic examinations, the mandibular second molar appeared to be the cause of the condition, the deep caries in the mandibular first molar convinced us to consider this tooth as the origin of the lesion.



**Figure 1.** Pre-treatment periapical radiograph of mandibular first and second molars shows lytic foci in association with permanent second molar



**Figure 2.** Pretreatment occlusal radiograph of dense paracortical mass (left side of mandible, FM: first molar, SM: second molar, black arrow: center of the lesion)

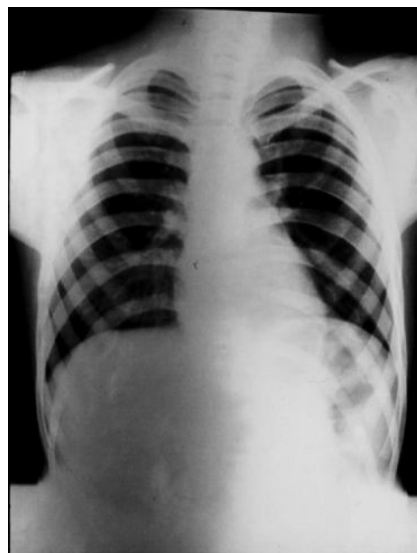


**Figure 3.** Preoperative skull Waters view

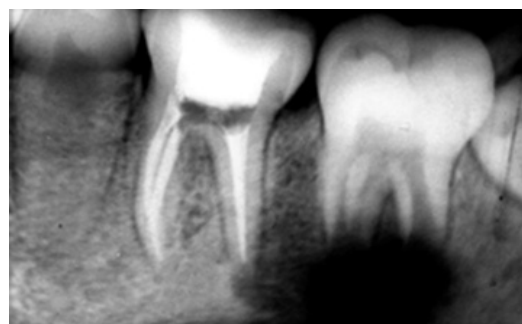In contrast to the lower right first molar, the lower left first and second molars and the lower right second molar did not respond to vitality pulp tests (electrical and thermal tests).

One-visit non-surgical endodontic treatment of the lower left first molar was planned. Following local anaesthesia with 2% lidocaine containing 1:80000 epinephrine (Darou Paksh, Tehran, Iran), caries were removed and an endodontic access cavity was prepared under rubber dam isolation. The root canals were prepared with the crown-down method using ProTaper Ni-Ti rotary instrumentation (Dentsply, Maillefer, Ballaigues, Switzerland). Irrigation between each instrument was performed using saline, 5.25% sodium hypochlorite and 17% EDTA. The canals were dried with absorbent paper points (Ariadent, Tehran, Iran), and filled using cold lateral compaction with gutta-percha

(Ariadent, Tehran, Iran) and a root canal sealer (AH-plus; Dentsply, Tulsa, OK, USA) (Figure 5). Antibiotics were not prescribed.

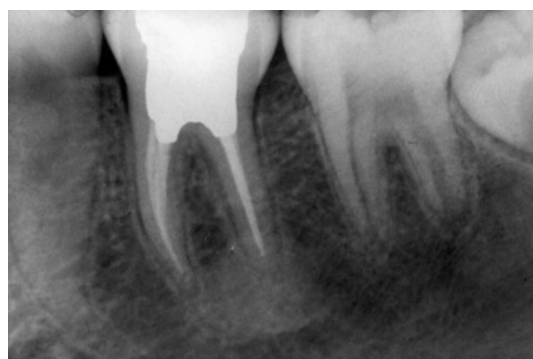

**Figure 4.** Chest x-ray; radiographic examination of the lungs, heart, large arteries, ribs, and diaphragm shows normal appearance

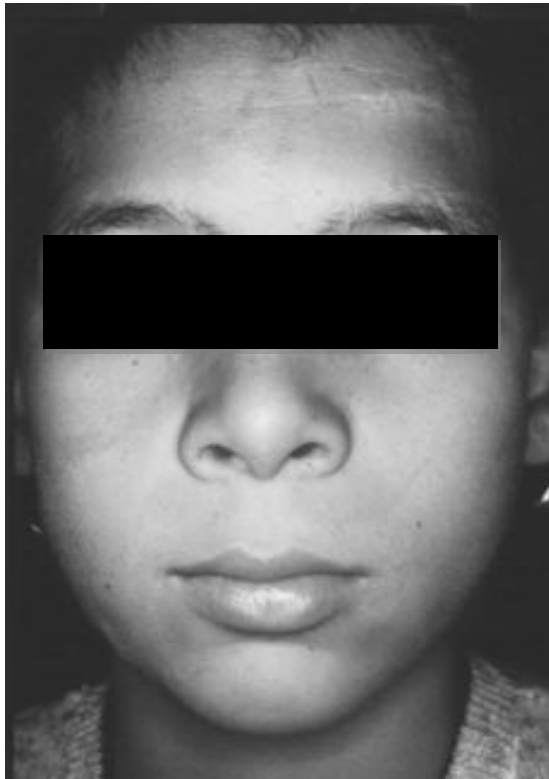


**Figure 5.** Mandibular left first molar at completion of endodontic treatment

After one week, the tooth was restored coronally with amalgam. The patient was seen after 3 months; he reported no symptoms and the lesion had significantly reduced in size (approximately 50%). Extraoral asymmetry was disappeared after one year. The periapical radiograph of the lower left first and second molars also showed complete periradicular healing and thorough development of the second molar apices at  $\approx 2$ -year follow-up (Figure 6-7).



**Figure 6.** One year after endodontic treatment; periapical radiolucent area is completely filled in with normal bone



**Figure 7.** Extraoral symmetry after one year

### 3. Discussion

Bone formation, as a result of periosteal reaction, occurs secondary to a number of bony pathosis and is not unique to the jawbones. In the orthopaedics, proliferative periostitis of the tibia is a well-known pathology and usually involves the anterior aspect of the tibia[7]. A same appearance can be found in osteomyelitis, trauma, several neoplastic diseases, fibro-osseous lesions and proliferative periostitis of Garrè [15-17]. In this case, the diagnosis of proliferative periostitis was confirmed after performing the serologic, immunologic and complete blood tests, in addition to radiographic examination of skull, jaws, and chest.

However, the presence of proliferative periostitis surrounding an adjacent tooth is rare to say the least. In previous reported cases, the lesions were found surrounding the offending tooth[6,9, 18-20]. In the present case, the distal root apex of lower left first molar was connected to the periapical lesion of adjacent second molar, and as the first molar suffered from a necrotic pulp, the lesion was undoubtedly caused by the first molar. Non-surgical root canal treatment can effectively eliminate etiological factors (i.e. microorganisms and their by-products) and therefore other treatments or adjunct antibiotic therapy was not deemed necessary[21]. The previous school of thought advocated surgical re-contouring of bone[22]; however, more recent evidence demonstrates that after good non-surgical root canal therapy, bone remodelling would take place physiologically[6] as the bone is re-contoured by the functional forces[3].

Pulp exposures from caries can cause pulpal infection which eventually results in periapical disease. The bacteria and their inflammatory by-products pass through spongy and cortical bone and reach beneath the periosteum. They stimulate periosteal osteoblasts, leading to apposition of new bone. With periodic irritation/stimulation, this process repeats several times and new bone is added to the previous bone in layers. Radiographic examination shows bony laminations parallel to each other and to the cortical surface of the involved bone[23-25]. Appropriate radiographic angulation may bring out the radiolucent zone of soft tissue between the bony cortex and the newly formed laminations. This characteristic phenomenon is described as an "onion skin appearance" in occlusal radiography[9-11].

Since non-surgical endodontic treatment removes the etiologic factors, it allows osteoblastic activity to be replaced by osteoclastic activity. After a certain period of time, the bone surface will remodel to its condition before the disease. The majority of articles have reported approximately one year time span for complete healing; this is consistent with our clinical finding[9,26-28].

### 4. Conclusions

The epicentre of the odontogenic proliferative periostitis can be seen at the adjacent normal tooth. Care must be taken to set the correct treatment plan. The results of this case study show that one-visit non-surgical endodontic management without antibiotic therapy can be the treatment of choice in odontogenic proliferative periostitis.

### ACKNOWLEDGMENTS

The authors wish to thank staff of Iranian Center for Endodontic Research as well as Iran Center for Dental Research who assisted in the preparation of this report.

### Conflict of Interest

The author(s) declare no conflict of interests

### REFERENCES

- [1] Garrè C. Ueber besondere Formen und Folgezustände d. akuten infekt. Osteomyelitis Beitr z klin Chir. 1893;10:257
- [2] Loveman CE. Mandibular subperiosteal swelling in children. J Am Dent Assoc 1941;28:1230-5
- [3] Wood NK, Goaz PW. Solitary radiopacities not necessarily contacting teeth. In: Wood NK, Goaz PW. Oral and maxillofacial lesions. 5th ed. St Luis: Mosby. 1996: 488-492
- [4] Eversole LR. Proliferation periostitis of Garrè: its differentiation from other neoperiostoses. J Oral Surg. 1979; 37(10):

725-31

- [5] Pell GJ. Garrè's osteomyelitis of the mandible: report of case. *J Oral Surg.* 1955;13(3):248-52
- [6] Zand V, Lotfi M, Vosoughhosseini S. Proliferative periostitis: a case report. *J Endod.* 2008;34(4):481-3
- [7] Tong ACK, Ng IOL, Au Yeung KM. Osteomyelitis with proliferative periostitis: an unusual case. *Oral Surg Oral Med Oral Pathol Oral Radiol Endod* 2006; 102:e14-e19
- [8] Lee L. Inflammatory lesions of the jaws. In: White Sc, Pharoah MJ. *Oral Radiology.* 5th ed. St Luis: Mosby. 2004:377-380
- [9] McWalter GM, Schaberg SJ. Garrè's osteomyelitis of the mandible resolved by endodontic treatment. *J Am Dent Assoc.* 1984;108(2):193-5
- [10] Smith SN, Farman AG. Osteomyelitis with proliferative periostitis (Garrè's osteomyelitis). Report of a case affecting the mandible. *Oral Surg.* 1977;43(2):315-8
- [11] Schwartz S, Pham H. Garrè's osteomyelitis: A case report. *Pediatr Dent.* 1981;3(3):283-6
- [12] Nortje CJ, Wood RE, Grotepass F. Periostitis ossificans versus Garrè's osteomyelitis: part II—radiologic analysis of 93 cases in the jaws. *Oral Surg Oral Med Oral Pathol* 1988;66(2):249-60
- [13] Lichty G, Langlais RP, Aufdemorte T. Garrè's osteomyelitis. *Oral Surg.* 1980;50(4):309-13
- [14] Wood RE, Nortjt CJ, Grotepass F, Schmidt S, Harris AMP. Periostitis ossificans versus Garrè's osteomyelitis. Part I. What did Garre really say? *Oral Surg Oral Med Oral Pathol Oral Radiol Endod.* 1988;65(6):773-7
- [15] Yadavalli G. Fibro-osseous Lesions of the Jaw: A Report of Two Cases. *J Clin Imaging Sci.* 2011;1:10
- [16] Pape HC, Zwipp H, Regel G, Hoffmann M, Maschek H, Tscherne H. Chronic treatment refractory osteomyelitis of long tubular bones--possibilities and risks of intramedullary boring. *Unfallchirurg.* 1995;98(3):139-44
- [17] Toller MO, Karaca I. Mandibular central giant cell granuloma associated with sclerosing osteomyelitis of Garrè (periostitis ossificans). Case report. *Aust Dent J.* 1993;38(2):119-24
- [18] Concalves M, Pinto Oleveira D, Oliveira Oya E, Concalves A. Garrè's osteomyelitis associated with a fistula: A case report. *J Clin Pediatr Dent.* 2002;26(3):311-3
- [19] Oulis C, Berdousis E, Vadiakas G, Goumenos G. Garres osteomyelitis of an unusual origin in a 8 year old child: A case report. *Int J Pediatr Dent* 2000;10(3): 240-4
- [20] Batcheldor GD, Giansanti JS, Hibbard ED, Waldron CA. Garre's osteomyelitis of the jaws: A review and report of two cases. *J Am Dent Assoc* 1973;87(4): 892-7
- [21] Sueti Y, Taguchi A, Tanimoto K. Diagnosis and classification of mandibular osteomyelitis. *Oral Surg Oral Med Oral Pathol Oral Radiol Endod* 2005;100(2): 207-14
- [22] Ellis DJ, Winslow JR, Indovina AA. Garrè's osteomyelitis of the mandible. *Oral Surg.* 1977;44(2):183-9
- [23] Kadom N, Egloff A, Obeid G, Bandarkar A, Vezina G. Juvenile mandibular chronic osteomyelitis: multimodality imaging findings. *Oral Surg Oral Med Oral Pathol Oral Radiol Endod.* 2011;111(3):e38-43
- [24] Suma R, Vinay C, Shashikanth MC, Subba Reddy VV. Garre's sclerosing osteomyelitis. *J Indian Soc Pedod Prev Dent.* 2007;25 Suppl:S30-3
- [25] Kannan SK, Sandhya G, Selvarani R. Periostitis ossificans (Garrè's osteomyelitis) radiographic study of two cases. *Int J Paediatr Dent.* 2006;16(1):59-64
- [26] Ferreina BA, Barbosa AL. Garre's osteomyelitis: A case report. *Int Endod J.* 1992;25(3):165-8
- [27] Mattison GD, Gould AR, George DI, Neb JL. Garre's osteomyelitis of the mandible: the role of endodontic therapy in patient management. *J Endod* 1981;7(12): 559-64
- [28] McWalter GM, Schaberg SJ. Garrè's osteomyelitis of the mandible resolved by endodontic treatment. *J Am Dent Assoc* 1984;108(2):193-5